

Medical University of South Carolina

**MEDICA**

---

MUSC Theses and Dissertations

---

2021

## Accuracy in Orienting Profile Photographs, Lateral Cephalographs, and Lateral CBCT Images to Natural Head Orientation (NHO)

Carolyn R. Whittow

*Medical University of South Carolina*

Follow this and additional works at: <https://medica-musc.researchcommons.org/theses>

---

### Recommended Citation

Whittow, Carolyn R., "Accuracy in Orienting Profile Photographs, Lateral Cephalographs, and Lateral CBCT Images to Natural Head Orientation (NHO)" (2021). *MUSC Theses and Dissertations*. 579.

<https://medica-musc.researchcommons.org/theses/579>

This Thesis is brought to you for free and open access by MEDICA. It has been accepted for inclusion in MUSC Theses and Dissertations by an authorized administrator of MEDICA. For more information, please contact [medica@muscu.edu](mailto:medica@muscu.edu).

# Accuracy in Orienting Profile Photographs, Lateral Cephalographs, and Lateral CBCT Images to Natural Head Orientation (NHO)

by

Carolyn R. Whittow

A thesis submitted to the faculty of the Medical University of South Carolina in partial fulfillment of the requirement for the degree of Masters of Science in Dentistry in the College of Dental Medicine.


Department of Orthodontics

Approval Date:


Approved by:

  
\_\_\_\_\_


Dr. Timothy Trement  
Chairman Advisory Committee

  
\_\_\_\_\_


Dr. Loring Ross

  
\_\_\_\_\_

Dr. Kinon Lechlop

  
\_\_\_\_\_

Dr. Idleu Andrade

  
\_\_\_\_\_

Dr. Pinar Emecen-Huja

## Accuracy in Orienting Profile Photographs, Lateral Cephalographs, and Lateral CBCT Images to Natural Head Orientation (NHO)

### ABSTRACT

**Introduction:** The purpose of this study was to (1) assess the ability of orthodontists and surgeons to accurately orient pretreatment lateral facial photographs, lateral cephalographs, and lateral CBCT facial images relative to a clinically determined natural head orientation (NHO) and (2) to assess any difference between orthodontists and oral surgeons in orienting images to clinically determined NHO and relative to their years in practice. **Methods:** Lateral facial photographs, lateral cephalographs, and lateral CBCT images of four(4) pretreatment patients were selected, and rotated in 1° increments from -3° to +4°. A total of 96 images were evaluated by 79 orthodontists and 43 oral surgeons via survey. Survey participants were asked to select which image in each image group best represented NHO. **Results:** Seventy-eight percent (78.1%) of all respondents were able to identify and agree on a NHO across all types of images studied that also agrees with the clinical impression of NHO within  $\pm 2^\circ$ ; however, the entire range of images was selected as representing NHO within each image type. The results indicate there were statistical differences between CBCT & photographs ( $p < 0.05$ ) and cephalographs ( $p < 0.05$ ), but not photographs and cephalographs. The difference between CBCTs and both photographs and cephalographs was approximately 1.2°. A statistically significant difference was found but between orthodontists and oral surgeons ( $p < 0.05$ ) for photographs, but the difference was 0.4°. There were some differences between certain groups by years of practice ( $p < 0.05$ ), but those differences were less than 1°. There was a statistically significant difference by those respondents with 31+ years of experience, but, again, the difference was less than 1°. **Conclusions:** Most orthodontists and oral surgeons can reliably orient lateral facial photographs, lateral cephalographs, and lateral CBCT images within  $\pm 2^\circ$  relative to a clinically determined NHO. There was significant difference in the ability to orient lateral CBCT images.

### Introduction

In orthodontics and orthognathic surgery, orientation of the head is an important for accurate diagnosis, treatment planning, and outcomes.<sup>1 2 3</sup> Valid and reliable landmarks and reference planes are essential. Arnett's research found that reliance on traditional cephalometric standards in some instances may lead to less than desirable facial outcomes. For example, the soft tissue covering the teeth and bone can vary so greatly that the dentoskeletal pattern may be inadequate in evaluating facial disharmony.<sup>1</sup> Current analyses utilize internal and external hard tissue and/or soft tissue planes to orient the head. Common methodologies include Frankfort Horizontal Plane (FH), Sella-Nasion plane (SN), the optic plane, true horizontal (HOR) or vertical (VER), natural head position (NHP), and natural head orientation (NHO), among others.<sup>2</sup>

The Frankfort-Horizontal plane and Sella-Nasion plane are the most well-known and commonly used internal hard tissue reference planes. Frankfort Horizontal is an anatomic reference line constructed using the cephalometric landmarks of porion and orbitale. However, orientation of the head using Frankfort horizontal may vary considerably from the true horizontal when an individual is placed in natural head position(NHP).<sup>3 4 5</sup> Moorrees<sup>6</sup> defined NHP as the position of the head when the subject looks at a distant point at eye level and their visual axis is parallel

to the ground. He advocated the use of a mirror to simulate looking toward the horizon.<sup>6 7 8</sup> NHP represents a true-life appearance of human beings, giving it realistic significance. Zebeib and Naini found a considerable range of variation, nearly 16 degrees, when Frankfort Horizontal was compared relative to NHP.<sup>6 9</sup> Collectively, Moorrees, Lundstrom, and Cooke<sup>6 10 11 12</sup> found NHP to be reproducible in the sagittal plane using cephalometric radiography and photography with deviations ranging from 1.3 to 2.2 degrees. This is considerably less variation than when compared to Frankfort horizontal. New cephalometric analyses therefore rely on it, rather than on intracranial reference lines, for diagnosis and treatment planning.<sup>4 13</sup>

Lundstrom introduced the concept of natural head orientation (NHO) in the 1990's.<sup>8 12 14</sup> NHO is defined as the orientation estimated by a trained clinician while the subject stands with a relaxed body and head and looks at a distant point at eye-level. This position is adjusted by the clinician to look more "natural."<sup>2 15</sup> NHO mitigated the problem of patients inadvertently flexing or extending their heads.

Various methods of recording the NHP or NHO have been developed to transfer the clinical impression to orthodontic/orthognathic treatment records for analysis and treatment planning such as photographs, lateral cephalographs, and lateral CBCT images.<sup>2</sup> This historically included orienting the patient's head and then utilizing a plum line as a true vertical reference while cephalometric radiographs and extraoral photographs are captured. Several measuring devices have been developed to assist with this transfer of a prearranged head position to the cephalostat or photograph, such as a fluid level device, inclinometer, or laser and radiographic markers on a subject's face. However, there are inherent difficulties in capturing these records that may produce an altered image. For example, the insertion of two ear rods in cases in which the right and left ears are asymmetrical results in vertical and/or horizontal rotation of the head.<sup>2 16 17</sup>

With the advent of 3-dimensional imaging for orthodontic and orthognathic treatment planning utilizing cone beam computed tomography (CBCT), new protocols for capturing head orientation have been proposed. Due to the long scan time (20-40s) needed to capture a full head CBCT, the patient's head must be fixed to avoid movement, thus the head position recorded may be reflective of the constraints as opposed to the desired position of the head.<sup>2 13</sup> Several methods have been described in the literature to record the head orientation and re-establish the head position using software which involves digital bite jigs and facebows, glass spheres, leveling lasers, or 3-dimensional camera systems.<sup>18</sup> Xia et al.<sup>18</sup> and Koerich de Paula et al.<sup>19</sup> demonstrated 3-dimensional reproducibility of NHP with minisensors in capturing changes within 6 degrees of freedom using stereophotogrammetry.<sup>12 19 18</sup> According to Gunson & Arnett, despite these developments in technology and their reproducibility, "It is surprising that surgeons spend very little time reviewing the orientation of the skull when using 3D virtual planning treatment planning services."<sup>20</sup>

Research defining true vertical and true horizontal using photographs, lateral cephalographs, and CBCT images relative to a clinically determined natural head orientation (NHO) is lacking. The purpose of this study was to assess the ability of orthodontists and surgeons to accurately orient pretreatment lateral facial photographs, lateral cephalographs, and lateral CBCT facial images relative to a clinically determined natural head orientation (NHO). The null hypotheses was: there is no difference in the judgement of natural head orientation (NHO) of a profile

photographs, b) 2D lateral cephalographs, and c) lateral CBCT images relative to a clinically judged natural head orientation (NHO). A secondary purpose was to evaluate any differences between orthodontists and oral surgeons and years of experience. The null hypotheses were: 1) there is no difference between orthodontists and oral surgeons in the judgement of natural head orientation (NHO) of a) profile photographs, b) 2D lateral cephalographs, and c) lateral CBCT images relative to a clinically judged natural head orientation (NHO). 2) For the combined images, there is no difference in the judgement of natural head orientation (NHO) relative to a clinically judged natural head orientation (NHO) based on years of practice experience.

## **Materials and Methods**

This study was approved by the Medical University of South Carolina's Institutional Review Board (ID #5750). A survey was developed using images from pre-treatment clinical records from the orthodontic and oral surgery departments of the MUSC College of Dental Medicine between 2019-2021. Any subjects age 18 or older were eligible to be included in the study if the record contained a full field of view head CBCT, lateral cephalometric radiograph, a profile and smiling photograph with millimetric ruler and a recorded clinical judgement of true vertical measurement for each patient. Exclusion criteria were as follows: (1) absence of or poor quality full-head FOV CBCT, (2) absence of smiling and repose photograph without millimetric ruler (3) absence of a recorded clinical judgement, (4) records of patients with craniofacial syndrome or gross asymmetries. Four (4) subjects were randomly chosen with adequate records to use in the study.

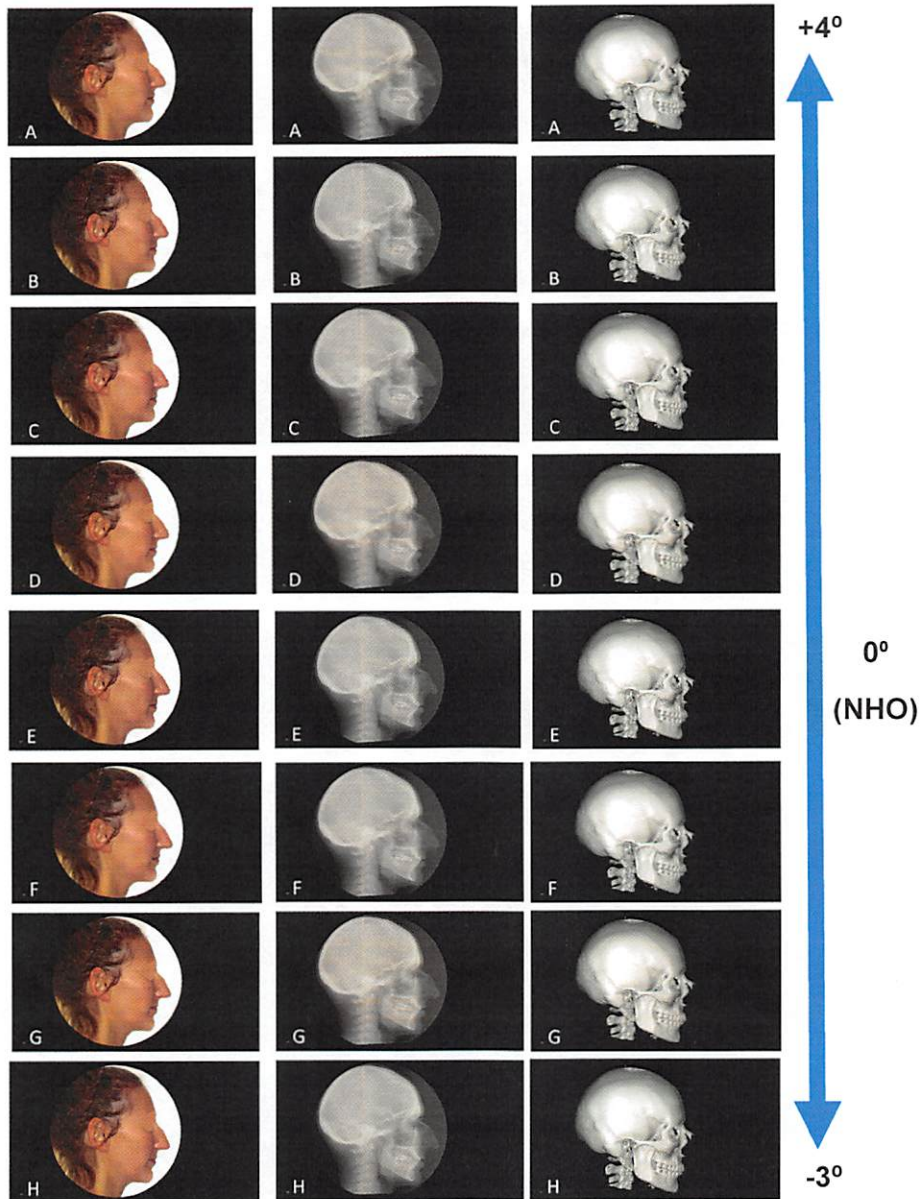
The clinical judgement of NHO was visually determined by a trained orthodontist (TT) and confirmed with a measurement device comprised of a horizontal millimetric ruler as described by previous studies.<sup>21 22</sup> The device was set to soft tissue glabella, a pointer set to the most anteriorly positioned upper central incisor, and a level used to confirm accurate judgement of the incisor to Glabella. A second orthodontist recorded a clinical measurement for all subjects to confirm reliability of the measurement as part of standard clinic protocols.

Initial diagnostic records included a profile and lateral photograph with millimetric ruler even with the subject's midsagittal plane. The repose profile photographs were deidentified with eye and eyebrow coverage as required by the MUSC IRB. The CBCT scans were obtained by Planmeca ProMax (Hoffman Estates, IL) using a 12-inch field of view. The volumetric data were reconstructed with  $0.58 \times 0.58 \times 0.69$  mm voxels and 1.2mm slices. The profile, cephalometric radiographs, and CBCT images were transferred to Microsoft PowerPoint™ (2019, Redmond, WA). All images were first calibrated for size using a digital ruler. The lateral cephalograph was first oriented to the clinically judged NHO using the digital ruler and the upper incisor to glabella vertical measurement. The images were rotated until the central incisor was then set to the same position as documented with the measurement device.<sup>21 22</sup> Then, the photograph and CBCT were oriented to clinical NHO using the relationship of the chin to glabella vertical from the lateral cephalograph. For the CBCT, a lateral volumetric image with millimetric ruler and soft tissue overlay was captured in order to calibrate the image using the same landmarks (i.e. soft tissue glabella and central incisor) as the photographs and lateral cephalograph. With the head oriented in the same position, the soft tissue overlay was removed, and image exported. The screen shot of the CBCT with soft tissue removed was set in the same manner. All images were converted to a circular format and all extraneous objects [vertical line, horizontal line, and ruler]

were virtually removed from the images to avoid the possible influence of visualizing the conventional straight edges of the images<sup>9 15</sup> These modified images were oriented to match the clinical impression (Figure 1, Image E). A series of images rotated in 1° increments above and below the image that represented the clinical record (-3° to +4°) were created and imported into a survey (Figure 1).

A REDCap (Research Electronic Data Capture, Vanderbilt University Nashville, Ten) survey was disseminated to orthodontists and oral surgeons who had no prior knowledge of the study hypothesis. The survey was distributed to 500 orthodontists via the AAO Member Directory website and 200 oral surgeons via the SC Association of Oral Surgeons and the AAOMS programs director list. Respondents were asked to select the image that best represented (NHO) of 1) profile photographs, 2) lateral cephalographs, and 3) profile views of CBCT 3D volumetric rendering. The following definition of NHO was provided at the beginning of the survey: "Natural head orientation is the position of a patient's head while they are looking forward towards a distance point at eye level. The operator can tip the patient's head up or down until it looks most upright and natural." Participants then selected their responses. All incomplete surveys were deleted. Information on profession (orthodontist or oral surgeon) and number of years in practice were collected. Respondents were divided into 4 groups based on years of practice: 1-5 years, 6-15 years, 16-30 years, and over 31 years.

**Figure 1.** Example of survey image series (photograph, cephalograph, & CBCT with head oriented in 1° increments.



### *Statistical Analysis*

Statistics were generated using SAS software, SAS Studio, SAS System. Copyright © 2021 SAS Institute Inc. Descriptive statistics (mean, standard deviation, range) were used analyzed to identify the extent that the images selected deviated from the clinical judgement of (NHO) by image type and profession. Differences were considered significant if  $p < 0.05$ . A frequency table was generated to determine the percentage of respondents who selected the clinical judgment of NHO within 1 or 2°. A chi-square test was used to determine whether there was relationship

between image selected as NHO and type of image. A series of generalized linear regression models were run to establish and quantify relationships between image types (photograph, cephalograph, CBCT) and image chosen. Two-way ANOVA models were run to determine how factors such as profession and years of practice may affect the image chosen by respondents to represent natural head orientation.

## Results

Seventy-nine (n=79) orthodontists and forty-three (n=43) oral surgeons completed the survey. Table 1 summarizes the percentage of responses that selected the NHO within  $\pm 1^\circ$  or  $\pm 2^\circ$  of the clinical head orientation. Nearly 54% of survey respondents selected the image within  $\pm 1^\circ$  of the clinical NHO, whereas 78.1% selected the image within  $\pm 2^\circ$  of the clinical NHO.

**Table 1.** Percentage of responses that selected the NHO within  $\pm 1^\circ$  or  $\pm 2^\circ$  of the clinical head orientation.

Image Type	Profession	NHO Within $\pm 1^\circ$ (-1,0,+1)	NHO Within $\pm 2^\circ$ (-2,-1,0,+1,+2)
Overall (Photo, ceph, CBCT)	Combined	53.6%	78.1%
Photograph	Combined	51.2%	73.9%
	Orthodontists	50.6%	75.3%
	Oral Surgeons	52.3%	71.5%
Cephalograph	Combined	59.8%	84.8%
	Orthodontists	62.6%	86.7%
	Oral Surgeons	54.6%	81.4%
CBCT	Combined	50.0%	77.8%
	Orthodontists	51.9%	76.9%
	Oral Surgeons	52.3%	78.4%

The descriptive statistics shown in Table 2 reflect the extent that the images selected by respondents as natural head orientation deviated from clinical judgement of NHO by type of image (photograph, cephalograph, CBCT) and profession. The combined means and standard deviations for each image type was:  $-0.3^\circ \pm 1.9^\circ$  for photographs,  $-0.3^\circ \pm 1.7^\circ$  for cephalographs, and  $-0.9^\circ \pm 1.8^\circ$  for CBCT. The means and standard deviation for orthodontists for each image type was  $-0.2^\circ \pm 2.0^\circ$ ,  $-0.2^\circ \pm 1.6^\circ$ , and  $1.0^\circ \pm 1.8^\circ$  for photograph, cephalograph, and CBCT, respectively. The means and standard deviation for oral surgeons was  $-0.6^\circ \pm 1.9^\circ$ ,  $-0.4^\circ \pm 1.8^\circ$ , and  $0.7^\circ \pm 1.9^\circ$  for photograph, cephalograph, and CBCT, respectively. The range of responses included all answer choices ( $-3.0^\circ$  to  $4.0^\circ$ ) for all categories.

**Table 2.** Mean, standard deviation, and range by type of image and profession.

Image Type	Profession	Mean ( $^\circ$ )	Standard Deviation ( $^\circ$ )	Minimum ( $^\circ$ )	Maximum ( $^\circ$ )
Photograph	Combined	-0.3	1.9	-3.0	4.0
	Orthodontists	-0.2	2.0	-3.0	4.0



Image Type	Profession	Mean (°)	Standard Deviation (°)	Minimum (°)	Maximum (°)
	Oral Surgeons	-0.6	1.9	-3.0	4.0
Cephalograph	Combined	-0.3	1.7	-3.0	4.0
	Orthodontists	-0.2	1.6	-3.0	4.0
	Oral Surgeons	-0.4	1.8	-3.0	4.0
CBCT	Combined	0.9	1.8	-3.0	4.0
	Orthodontists	1.0	1.8	-3.0	4.0
	Oral Surgeons	0.7	1.9	-3.0	4.0

Table 3 shows the frequency distribution of total responses by image type (photograph, cephalograph, and CBCT). A chi-square test was used to determine whether there was a relationship between which image was selected as representing NHO and the type of image. There was a statistically significant difference between the type of image and which image was selected ( $\chi^2(14, 1,464) = 150.8, p < 0.0001$ ).

**Table 3.** Frequency distribution of total responses for orthodontists and oral surgeons combined.

Orthodontists and Oral Surgeons Combined				
	Type of Image			
	Photograph	Cephalograph	CBCT	Total
<b>A</b>	19 3.89%	9 1.84%	43 8.81%	71
<b>B</b>	26 5.33%	15 3.07%	55 11.27%	96
<b>C</b>	45 9.22%	46 9.43%	88 18.03%	179
<b>D</b>	73 14.96%	83 17.01%	103 21.11%	259
<b>E</b>	84 17.21%	111 22.75%	93 19.06%	288
<b>F</b>	93 19.06%	98 20.08%	48 9.84%	239
<b>G</b>	66 13.52%	76 15.57%	36 7.38%	178
<b>H</b>	82 16.80%	50 10.25%	22 4.51%	154
<b>Total</b>	488	488	488	1464

A generalized linear regression model and Tukey post-hoc test (Table 4) was used to determine the differences in NHO by image type. There were statistical differences between at least two of the groups ( $F=69.1$ ,  $p<0.0001$ ). There was no statistical difference between the means of the photographs and cephalographs, but there was a statistical difference (1.2 degrees) between photographs and CBCTs ( $p<0.05$ ) and cephalographs and CBCTs ( $p<0.05$ ).

**Table 4.** Comparison of Image Types (Photograph, Cephalograph, CBCT)

Comparison of Image Types	Difference Between Means	Simultaneous 95% Confidence Limits		
		Lower	Upper	Significance
<b>CBCT vs cephalograph</b>	1.1762	0.9028	1.4497	*
<b>CBCT vs photo</b>	1.1967	0.9233	1.4701	*
<b>Photo vs cephalograph</b>	0.0205	-0.2529	0.2939	

Comparisons significant at the 0.05 level are indicated by \*.

To explore whether there were differences between oral surgeons and orthodontists in their selection of the image representing NHO within each type of image, we used independent samples t-tests (Table 5). The only statistical difference was found in the assessment of the photographs. The magnitude was approximately 0.4 degrees ( $p<0.05$ ).

**Table 5.** Differences between orthodontists and oral surgeons for photographs, Cephalographs, and CBCTs.

**Photographs**

Profession	N	Mean	Std Dev	Std Err	Minimum	Maximum
<b>Orthodontists</b>	316	-0.1835	1.9707	0.1109	-3.00	4.00
<b>Oral Surgeons</b>	172	-0.5581	1.8707	0.1426	-3.00	4.00
<b>Difference</b>		0.3746				
<b>t = 2.07, p=0.0388</b>						

**Cephalographs**

Profession	N	Mean	Std Dev	Std Err	Minimum	Maximum
<b>Orthodontists</b>	316	-0.2405	1.6191	0.0911	-3.00	4.00

Profession	N	Mean	Std Dev	Std Err	Minimum	Maximum
Oral Surgeons	172	-0.3953	1.7557	0.1339	-3.00	4.00
Difference		0.1548				
<b>t = 1.18, p=0.2196</b>						

#### CBCT

Profession	N	Mean	Std Dev	Std Err	Minimum	Maximum
Orthodontists	316	1.0000	1.7764	0.0999	-3.00	4.00
Oral Surgeons	172	0.6628	1.9383	0.1478	-3.0000	4.0000
Difference		0.3372				
<b>t = 1.19, p=0.1865</b>						

In terms of years of experience, clinicians with 31+ years of professional experience statistically differed from all other groups with less experience. The differences in each of the comparisons are less than 1° (two-way ANOVA with Tukey's post-hoc test). The only other statistically relevant finding is the difference between those with 6-15 years of experience and 0-5 years of experience; this difference is less than 0.5 degrees.

**Table 6.** Comparison of years in practice for all image types and all professions.

Comparison of years in practice	Difference Between Means	Simultaneous 95% Confidence Limits	
6-15 yrs vs. 16-30 yrs	0.3113	-0.0147	0.6373
6-15 yrs vs. 0-5 yrs	0.4626	0.0917	0.8335 *
6-15 yrs vs. 31+ yrs	0.8970	0.5642	1.2297 *
16-30 yrs vs. 0-5 yrs	0.1513	-0.2087	0.5113
16-30 yrs vs. 31+ yrs	0.5856	0.2650	0.9063 *

Comparison of years in practice	Difference Between Means	Simultaneous 95% Confidence Limits		
0-5 yrs vs. 31+ yrs	0.4343	0.0682	0.8005	*

Comparisons significant at the 0.05 level are indicated by \*.

Separate generalized linear model tests determined that there was no statistical difference between photographs and cephalographs for any of the four subjects, but there was a difference between photographs and CBCTs and cephalographs and CBCTs for each of the four subjects (Subject 1:  $F=18.64$ ,  $p<0.0001$ , Subject 2:  $F=11.41$ ,  $p<0.0001$ , Subject 3:  $F=33.98$ ,  $p<0.0001$ , Subject 4:  $F=20.72$ ,  $p<0.0001$ ).

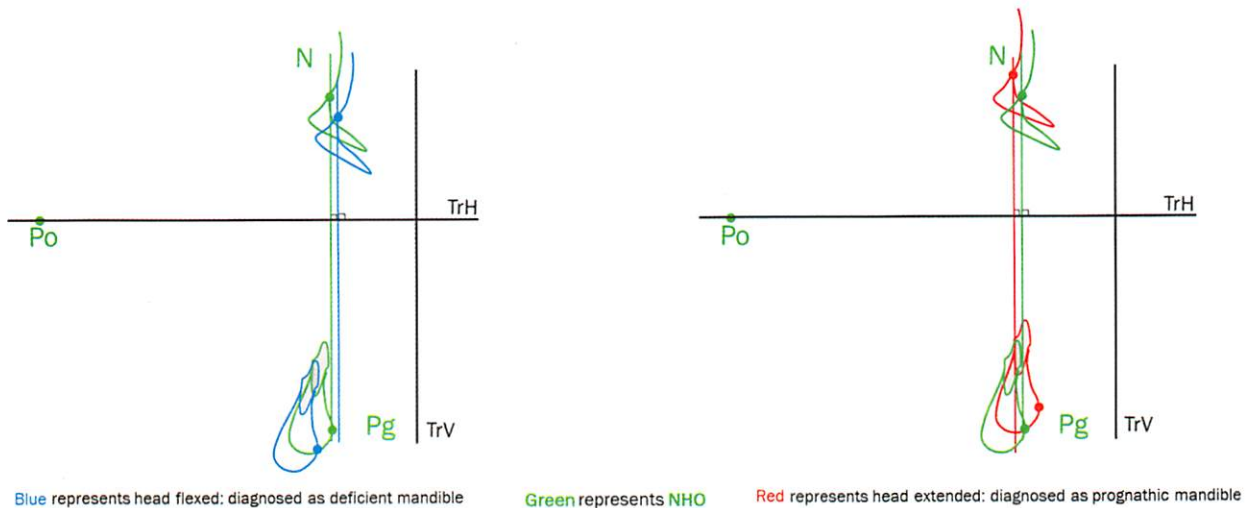
## Discussion

Orientations of the head is important for orthognathic surgical treatment planning. Both orthodontists and oral surgeons are involved in the design and treatment an orthognathic surgery case. Thus, the two professions should match regarding treatment evaluation and treatment planning. The purpose of this study was to assess the ability of orthodontists and surgeons to accurately orient pretreatment lateral facial photographs, lateral cephalographs, and lateral CBCT facial images relative to a clinically determined natural head orientation (NHO). A secondary purpose is to assess any difference between orthodontists and oral surgeons in orienting images to clinically determined NHO and relative to their years in practice.

Our results show that a high percentage of respondents identified the same NHO as the clinical operator (53.6% within  $\pm 1^\circ$  and 78.1% within  $\pm 2^\circ$ ). Nevertheless, the range of responses still included all answer choices. We reject the null hypothesis and found that there were statistical differences between CBCTs and photographs and cephalographs, but not between photographs and cephalographs.

It is important to recognize that variation in head orientation, even within a small range, may have clinical significance. Zebeib and Naini<sup>3</sup> found that a  $2^\circ$  alteration in head position either upward or downward will lead to a change in the sagittal position of pogonion of 4mm based on an average face height of 100mm.<sup>3</sup> Treatment outcomes could be affected by such alterations in pogonion position. Figure 2 demonstrates the geometry of such deviations.

**Figure 2.** Schematic diagram demonstrating the influence of head orientation on chin position. A  $4^\circ$  rotation in head position alters the sagittal position of pogonion in both vertical and horizontal dimensions. The green represents NHP position. The red represents  $4^\circ$  counterclockwise rotation and the blue represents  $4^\circ$  clockwise rotation with the center of rotation at porion (Po).



It is possible that some practitioners who participated in the survey may have never received any training regarding the concepts of NHO or NHP, despite that a definition was provided in the survey. In addition, we limited the number of images to eight per question due to the large number of images in which participants would have to scroll to view. Additional orientations may have been selected if more options had been available.

The tendency of the CBCT images was for respondents to select the image that was slightly “tipped up” compared to the clinical NHO. The statistical significance of the CBCT comparison could be explained by the fact that the soft tissue overlay was not included as part of the survey with the CBCT image. These findings suggest that the soft tissue could play a significant role in the ability of clinicians to accurately orient the head to NHO. Cevitanes et. al.<sup>23</sup> compared the orientation of intracranial reference planes to simulated NHP using CBCT models with a soft tissue overlay; however, these findings were not compared to a clinical recording, as in our study.<sup>23</sup>

In comparing orthodontists and oral surgeons, we reject the null hypothesis and conclude that there is a statistical difference between their choice of images that represent NHO, but the difference between the two professions is 0.4 degrees. Since this difference is smaller than the one-degree increments between images, it may not be of clinical significance.

Our study assumed that natural head orientation (NHO) is a valid head orientation to use in establishing true horizontal and true vertical reference planes, which has been previously discussed. This study also assumes that the mandible was recorded in the same position for the photographs, lateral cephalograph, and CBCT images as was the clinical measurement.

This study did not examine influences in facial form, but some studies have identified this as a complicating factor.<sup>2 24</sup> Halazonetis<sup>25</sup> examined whether NHO is influenced by facial morphology and found that NHO can be dependent on chin position. Our study did not find any statistical differences between subjects, but future studies could also examine other facial features, such as the nose, lips, eyes, or forehead, or craniofacial anomalies.

One of the limitations of this study was that the eyes and eyebrows were blocked out for the study in accordance with the protocols of the institutional review board. The geometric forms that were required in order to satisfy this request may have added a confounding variable to the study and made it more difficult for survey participants to assess the photographs. Nevertheless, most participants still selected NHO within  $\pm 2$  degrees of the clinical judgement.

Future studies may want to compare NHO to internal landmarks such as Frankfort horizontal or sella-nasion in 3-dimensions. A frontal view was not evaluated in this study, but this is also a critical orientation that must be researched. The default of most surgical orthognathic virtual treatment planning software orients the head to FH in the sagittal view or the orbit in frontal view. Researchers may find that estimating NHO in 3D treatment planning software may be more valid than the default setting to Frankfort horizontal or the interpupillary line, even if no clinical recording was obtained. The practitioner must inform the software technician to adjust the head orientation. As virtual three-dimensional treatment planning gains in popularity and potential to improve outcomes, it is important that the search for valid and reliable reference planes to continue.

## Conclusions

1. Most orthodontists and oral surgeons can orient profile photographs, lateral cephalographs, and lateral CBCT images within  $\pm 1^\circ$  to  $\pm 2^\circ$  to natural head orientation (NHO) relative to a clinical NHO.
2. There is a statistically significant difference in orientation of CBCTs relative to NHO compared to photographs and cephalographs for both orthodontists and oral surgeons.
3. There is a statistically significant difference between orthodontists and oral surgeons in orientation of photographs. While statistically significant, the difference was only  $0.4^\circ$ .
4. For all the images combined, there is a statistically significant difference in orienting the images to NHO based on years of experience. While statistically significant, the difference was less than  $1^\circ$ .

## References

1. Arnett GW, Bergman RT. Facial keys to orthodontic diagnosis and treatment planning. part I. *Am J Orthod Dentofacial Orthop.* 1993;103(4):299-312.
2. Cassi D, De Biase C, Tonni I, Gandolfini M, Di Blasio A, Piancino MG. Natural position of the head: Review of two-dimensional and three-dimensional methods of recording. *Br J Oral Maxillofac Surg.* 2016;54(3):233-240.
3. Zebeib AM, Naini FB. Variability of the inclination of anatomic horizontal reference planes of the craniofacial complex in relation to the true horizontal line in orthognathic patients. *Am J Orthod Dentofacial Orthop.* 2014;146(6):740-747.
4. Madsen DP, Sampson WJ, Townsend GC. Craniofacial reference plane variation and natural head position. *Eur J Orthod.* 2008;30(5):532-540.
5. Tremont TJ. An investigation of the variability between the optic plane and frankfort horizontal. *American Journal of Orthodontics.* 1980;78(2):192-200.
6. Moorrees CFA, Kean MR. Natural head position, a basic consideration in the interpretation of cephalometric radiographs. *Am J Phys Anthropol.* 1958;16(2):213-234.
7. Moorrees CF. Natural head position--a revival. *American journal of orthodontics and dentofacial orthopedics.* 1994;105(5):512-513.

8. Lundström A, Forsberg CM, Westergren H, Lundström F. A comparison between estimated and registered natural head posture. *European journal of orthodontics*. 1991;13(1):59-64.
9. Jiang J, Xu T, Lin J. The relationship between estimated and registered natural head position. *Angle Orthod*. 2007;77(6):1019-1024.
10. Lundström F, Lundström A. Natural head position as a basis for cephalometric analysis. *Am J Orthod Dentofacial Orthop*. 1992;101(3):244-247.
11. Cooke MS, Orth D, Wei SHY. A summary five factor cephalometric analysis based on natural head posture and the true horizontal. *Am J Orthod Dentofacial Orthop*. 1988;93(3):213-223.
12. Weber DW, Fallis DW, Packer MD. Three-dimensional reproducibility of natural head position. *Am J Orthod Dentofacial Orthop*. 2013;143(5):738-744.
13. Damstra J, Fourie Z, Ren Y. Simple technique to achieve a natural position of the head for cone beam computed tomography. *British journal of oral & maxillofacial surgery*. 2009;48(3):236-238.
14. Lundström A, Lundström F. The frankfort horizontal as a basis for cephalometric analysis. *Am J Orthod Dentofacial Orthop*. 1995;107(5):537-540.
15. Lundström A, Lundström F, Lebrecht LM, Moorrees CF. Natural head position and natural head orientation: Basic considerations in cephalometric analysis and research. *Eur J Orthod*. 1995;17(2):111-120.
16. Verma SK, Maheshwari S, Gautam SN, Prabhat K, Kumar S. Natural head position: Key position for radiographic and photographic analysis and research of craniofacial complex. *J Oral Biol Craniofac Res*. 2012;2(1):46-49.
17. Üşümez S, Orhan M. Reproducibility of natural head position measured with an inclinometer. *Am J Orthod Dentofacial Orthop*. 2003;123(4):451-454.
18. Xia JJ, McGrory JK, Gateno J, et al. A new method to orient 3-dimensional computed tomography models to the natural head position: A clinical feasibility study. *J Oral Maxillofac Surg*. 2011;69(3):584-591.
19. Koerich de Paula L, Ackerman JL, Carvalho, Felipe de Assis Ribeiro, Eidson L, Soares Cevidanes LH. Digital live-tracking 3-dimensional minisensors for recording head orientation during image acquisition. *American journal of orthodontics and dentofacial orthopedics*. 2012;141(1):116-123.
20. Gunson MJ, Arnett GW. Orthognathic virtual treatment planning for functional esthetic results. *Seminars in orthodontics*. 2019;25(3):230-247.
21. Anderson R, Tremont T. *Validity of three cephalometric analyses for diagnosis of the anteroposterior position of the maxilla*. Medical University of South Carolina; 2020.
22. Gavri A, Tremont T. *Optimal anteroposterior position of maxillary incisors in Caucasian females*. Medical University of South Carolina; 2020.
23. Cevidanes L, Oliveira AEF, Motta A, Phillips C, Burke B, Tyndall D. Head orientation in CBCT-generated cephalograms. *Angle Orthod*. 2009;79(5):971-977.
24. Zhu S, Keeling A, Hsung TC, Yang Y, Khambay B. The difference between registered natural head position and estimated natural head position in three dimensions. *Int J Oral Maxillofac Surg*. 2018;47(2):276-282.
25. Halazonetis DJ. Estimated natural head position and facial morphology. *Am J Orthod Dentofacial Orthop*. 2002;121(4):364-368. Accessed Apr 7, 2021.
26. Downs WB. The role of cephalometrics. *Am J Orthod*. 1952;38(3):162-182.
27. Petricevic N, Celebic A, Celic R, Baucic-Bozic M. Natural head position and inclination of craniofacial planes. *Int J Prosthodont*. 2006;19(3):279-280.
28. Peter S. Vig, B.D.S., Kevin J. Showfety, et al. Experimental manipulation of head posture. *American Journal of Orthodontics*. 1980;77(3):258-268.
29. Showfety KJ, Vig PS, Matteson S. A simple method for taking natural-head-position cephalograms. *Am J Orthod*. 1983;83(6):495-500.

30. Solow B, Tallgren A. Natural head position in standing subjects. *Acta Odontol Scand.* 1971;29(5):591-607. Accessed Apr 7, 2021.

31. Barbera AL, Sampson WJ, Townsend GC. Variation in natural head position and establishing corrected head position. *Homo.* 2014;65(3):187-200.

Possible authors and/or acknowledgements:

Carolyn R. Whittow

Timothy Tremont

Julie Marshall

Loring Ross

M. Kinon Lecholop

Ildeu Andrade

Matthew Miner

Martin Steed

Caroline McElveen